Journal of Otology 21 (2026) 208 – 215

Journal of Otology

journal homepage: www.sciopen.com/journal/1672-2930

Cochlear Implantation with Intracochlear Schwannoma In Situ in a Complex Mosaic NF2 Patient with Severe Visual Impairment: A Case Report and Literature Review

Boxiang Zhuang[1,2,3], Linling Fu[1,2,3], Dandan Wang[1,2,3], Mengdi Hong[1,2,3] and Jianan Li[1,2,3] ✉

[1] *Department of Otorhinolaryngology Head and Neck Surgery, Chinese PLA General Hospital, Beijing, China*

[2] *National Clinical Research Center for Otolaryngologic Diseases, Beijing, China*

[3] *National Key Laboratory of Hearing and Vestibular Medicine, Beijing, China*

ABSTRACT

Objective:To report the first Chinese case of complex mosaic neurofibromatosis type 2 (NF2)—recently reclassified as NF2-related schwannomatosis—in a patient presenting with concurrent severe visual impairment and an intracochlear schwannoma, and to evaluate the clinical efficacy and strategic priority of tumor-preserving *in situ* cochlear implantation (CI).Methods:The patient's clinical presentation, extensive neurosurgical history, genetic profile, and perioperative audiological data were retrospectively reviewed. Additionally, we analyzed the surgical approach —which involved localized microdrilling of the obstructed cochlear turn —and the subsequent one-year follow-up outcomes of auditory-verbal rehabilitation.Results: A 52-year-old female presented with bilateral vestibular schwannomas and secondary profound sensorineural hearing loss. Peripheral blood genetic testing revealed no pathogenic *NF2* mutations, strongly indicating somatic mosaicism. The patient also suffered from a concurrent profound visual deficit due to bilateral optic atrophy and exhibited a right-sided intracochlear schwannoma. Successful tumor-preserving in situ cochlear implantation (CI) was performed on her right ear by bypassing the tumor obstruction along the cochlear trajectory. At the one-year postoperative follow-up, the patient achieved significant gains in aided hearing thresholds, along with a disyllabic word recognition score of 22%. Furthermore, her Category of Auditory Performance (CAP) score markedly improved from 0 to 6, and her Speech Intelligibility Rating (SIR) score reached level 5.Conclusion:Cochlear implantation (CI) with tumor preservation *in situ* represents a safe, viable, and highly effective hearing reconstruction strategy for complex *NF2* patients with intracochlear schwannomas. For patients afflicted with dual sensory impairment (dual sensory loss), a successful cochlear implant serves as a critical standalone interface that significantly facilitates auditory-verbal rehabilitation and restores social autonomy, even within an intricate oncological landscape.

KEYWORDS

Neurofibromatosis type 2, Intracochlear schwannoma, Cochlear implantation, Case report.

1 Introduction

Neurofibromatosis type 2 (NF2) is a debilitating autosomal dominant disorder characterized by near-complete penetrance, in which the vast majority of individuals harboring a pathogenic germline mutation eventually manifest clinical symptoms (Pérez-Grau et al., 2010). Unlike neurofibromatosis type 1 (NF1) (Pérez-Grau et al., 2010; Tamura, 2021), NF2 typically presents before the third decade of life and is characterized by multiple schwannomas—predominantly bilateral vestibular schwannomas—meningiomas, and other benign central nervous system (CNS) tumors (Pérez-Grau et al., 2010; Ghalavand et al., 2023). Approximately 20% of NF2 patients without a relevant family history exhibit somatic mosaicism (Pérez-Grau et al., 2010). Along with NF1 and schwannomatosis, NF2 belongs to a broad category of hereditary tumor predisposition syndromes collectively termed neurofibromatoses, which feature peripheral nerve sheath tumors (Tamura, 2021); among these, NF2 accounts for roughly 3% of cases (Tamura, 2021; Brown, 2023). Because the progressive enlargement of vestibular schwannomas inevitably leads to sensorineural hearing loss, balancing tumor management with functional hearing reconstruction remains an essential yet highly formidable clinical challenge (Mankekar and Holmes, 2023).

2 Material and methods

2.1 Material

In March 2024, a 52-year-old female presented to our Department of Otorhinolaryngology–Head and Neck Surgery with a 17-year history of progressive left-sided hearing loss and a 3-year history of right-sided hearing impairment. A meticulous baseline

Peer review under responsibility of PLA General Hospital Department of Otolaryngology Head and Neck Surgery.

* Corresponding author Jianan Li, lijianan2005@126.com

https://doi.org/10.26599/JOTO.2026.9540075

Received 5 September 2025; Revised 21 July 2026; Accepted 18 August 2026

©2026 PLA General Hospital Department of Otolaryngology Head and Neck Surgery. Publishing services by Tsinghua University Press. This is an open access article under the CC BY-NC-ND license (http://creativecommons.org/licenses/by-nc-nd/4.0/).

clinical assessment was performed, encompassing a comprehensive medical history—including detailed timelines of the present illness, past medical and surgical histories, personal habits, menstrual history, and family genetic screening—followed by a systemic physical examination and specialized otological, audiological, and ophthalmological evaluations.

2.2 Methods

2.2.1 Audiological Testing

Pure-tone audiometry, tympanometry, distortion-product otoacoustic emissions (DPOAEs), auditory brainstem response (ABR), the 40 Hz auditory event-related potential (40-Hz AERP), and speech recognition scores (SRSs) were evaluated to systematically and comprehensively assess the functional integrity of the patient's peripheral and central auditory pathways.

2.2.2 Imaging and Auxiliary Examinations

Structural and functional evaluations comprised high-resolution computed tomography (HRCT) of the temporal bone, unenhanced magnetic resonance imaging (MRI) of the inner ear, contrast-enhanced brain MRI, electroencephalography (EEG), fundoscopy, and visual acuity assessments.

2.2.3 Auditory and Speech Ability Assessment

The Category of Auditory Performance (CAP) and Speech Intelligibility Rating (SIR) scales were utilized to quantify and track the longitudinal outcomes of the patient's postoperative auditory–verbal rehabilitation.

2.3 Ethical Approval

This study, which encompassed a retrospective clinical data analysis and prospective intraoperative evaluations, was approved by the Medical Ethics Committee of the Chinese PLA General Hospital (Approval No. S2025-245-01). All investigative procedures adhered strictly to the ethical tenets of the Declaration of Helsinki. Prior to enrollment, written informed consent was obtained from the patient (or her legal representative), specifically covering the prospective intraoperative cochlear electrophysiological testing components configured within this research framework.

3 Results

3.1 Clinical Manifestations

3.1.1 History of Present Illness

The patient's clinical history dated back to 2007, when she initially experienced persistent neck discomfort. Subsequent magnetic resonance imaging (MRI) revealed multiple meningiomas in the left cerebral hemisphere, a vestibular schwannoma, and spinal tumors. Specialized evaluations at that time confirmed complete anacusis in her left ear, whereas her right-sided hearing thresholds remained within normal limits; no other systemic symptoms were reported. She was diagnosed with NF2 at the First Affiliated Hospital of Chongqing Medical University and managed with conservative observation and regular follow-up.

In February 2021, the patient noted the onset of progressive hearing deterioration and persistent tinnitus in her previously stable right ear, while other neurological symptoms remained unchanged. Although a conventional hearing aid was trialed, it provided limited acoustic benefit. By November 2023, the right-sided tinnitus had exacerbated, and her hearing thresholds rapidly degenerated into profound sensorineural hearing loss. A follow-up contrast-enhanced magnetic resonance imaging (MRI) scan of the internal auditory canals (IACs) demonstrated bilateral vestibular schwannomas. She subsequently received seven courses of systemic targeted therapy with bevacizumab, which yielded only marginal auditory improvement. Consequently, the patient and her family presented to our department seeking cochlear implantation for hearing reconstruction. The definitive admission diagnoses were established as follows: bilateral profound sensorineural hearing loss, neurofibromatosis type 2 (NF2), and epilepsy.

3.1.2 Past Medical History

In January 2010, due to progressive bilateral visual field constriction, the patient underwent surgical resection of a left frontal meningioma at the First Affiliated Hospital of Chongqing Medical University. Postoperatively, her bilateral visual acuity rapidly deteriorated. Given the presence of residual intracranial tumor tissue, adjunctive Gamma Knife radiosurgery was performed once during the early postoperative period. In 2012, she underwent spinal tumor resection at West China Hospital, which permanently impaired her right lower limb motor dexterity. Subsequently, she underwent resection of a left occipital tumor in February 2015, achieving an uneventful and satisfactory postoperative recovery.

In July 2022, the patient experienced a generalized tonic-clonic seizure. Although multiple antiseizure medications (ASMs)—including levetiracetam, alprazolam, and topiramate—were regularly administered, her epilepsy remained suboptimally controlled and was accompanied by a progressive decline in right-sided limb function. To alleviate mass effect, a partial resection of the left-sided intracranial tumor was performed in January 2023, which successfully restored her right limb function and achieved significantly improved seizure control. Currently, she remains on strict maintenance ASM therapy. In February 2023, the patient developed sciatica and low back pain. Subsequently, on July 20, 2023, peripheral blood genetic testing performed at the First Affiliated Hospital of Chongqing Medical University revealed no pathogenic variants within the NF2 gene. Notably, the patient has a documented drug allergy to dexamethasone. Her family history was non-contributory; her parents, sister, and daughter were clinically asymptomatic and exhibited no phenotypic manifestations of the disease.

3.1.3 Clinical Examination

1) Specialized Physical Examination:

Upon admission, the patient presented with profound bilateral visual impairment; however, both direct and indirect pupillary light reflexes remained intact and consensual. Neurological examination of the cranial nerves revealed that tongue protrusion deviated significantly to the right, accompanied by noticeable muscular hemiatrophy and persistent fibrillations of the right hemicordate tongue. The remaining cranial nerve examinations demonstrated no significant pathological abnormalities.

2) Imaging Studies:

High-resolution computed tomography (HRCT) of the temporal bone demonstrated a pronounced enlargement of the left internal auditory canal (IAC), accompanied by adjacent bone resorption and erosion at the fundus, along with an abnormal soft-tissue density within the left tympanic cavity (Fig. 1a). Unenhanced

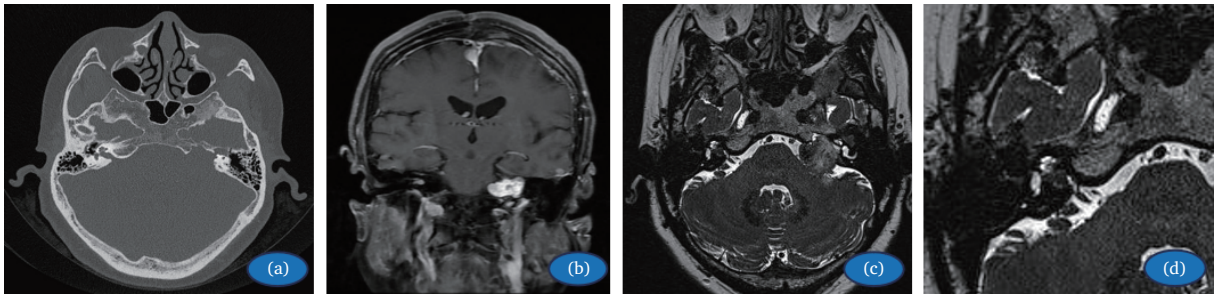

Figure 1 Imaging findings of the patient. (a) Temporal bone CT demonstrates pronounced enlargement of the left internal auditory canal (IAC), accompanied by adjacent bone resorption and erosion at the fundus, along with abnormal soft-tissue density within the left tympanic cavity. (b) Coronal contrast-enhanced brain MRI reveals a distinct tumor mass measuring approximately 21 mm × 22 mm within the left cerebellopontine angle (CPA). (c) Axial unenhanced MRI of the inner ear demonstrates bilateral IAC masses. (d) Magnified unenhanced MRI view of the right inner ear clearly delineates a distinct micronodule within the right IAC, with evident tumor extension into the basal turn of the right cochlea.

magnetic resonance imaging (MRI) of the inner ear revealed a well-defined mass within the left IAC and a distinct micronodule within the right IAC, highly suggestive of bilateral vestibular schwannomas (Fig. 1c). Furthermore, contrast-enhanced cranial MRI demonstrated a mass measuring approximately 21 mm × 22 mm within the left cerebellopontine angle (CPA), alongside multiple intracranial meningiomas pathognomonic of neurofibromatosis type 2 (NF2). Postoperative changes and encephalomalacia were noted in the left frontal and left occipital cortical regions, correlating closely with her documented surgical history. Additionally, mild chronic ischemic white matter changes were observed, consistent with a Fazekas grade 1 classification (Fig. 1b).

3) Audiological Examination:

Pure-tone audiometry indicated bilateral profound sensorineural hearing loss, with pure-tone averages (PTAs) of 120 dB HL in the left ear and 113 dB HL in the right ear (Fig. 2). Tympanometry demonstrated normal Type A curves bilaterally. Regarding auditory electrophysiological evaluations, both auditory brainstem response (ABR) and 40-Hz auditory event-related potential (40-Hz AERP) waveforms were completely absent bilaterally at the maximum stimulus intensity of 100 dB nHL. Furthermore, maximum speech discrimination scores were 0% bilaterally, and distortion-product

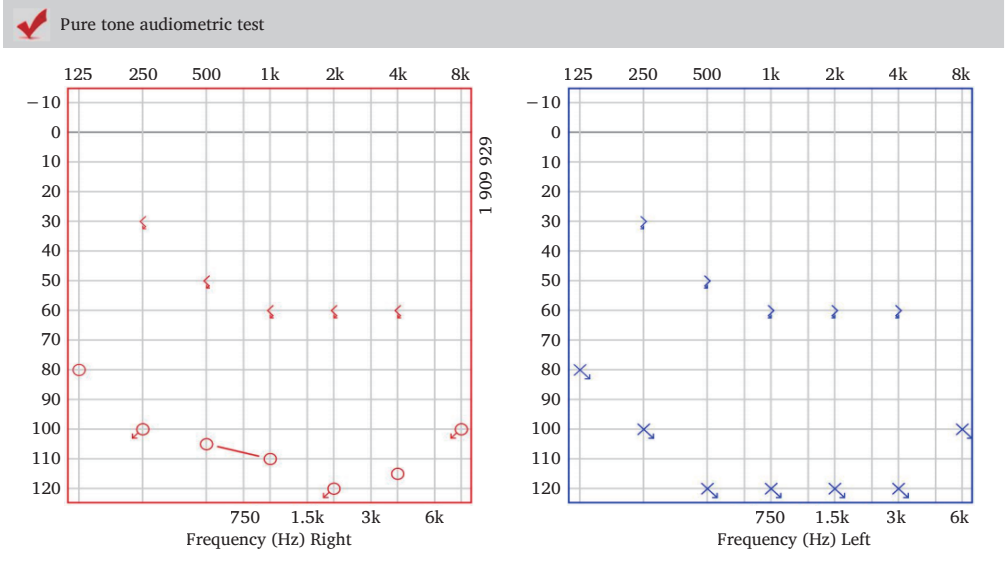

Speech recognition score

	Average hearing threshold (dB HL)	Stimulus intensity (masking intensity) (dB HL)	Maximum speech recognition score (%)	Maximum speech recognition threshold (dB HL)
Left ear	120	104	0%	
Right ear	113	104	0%	

Test material: Developed by the clinical hearing medicine center, department of otolaryngology-head and neck surgery

Figure 2 Preoperative pure-tone audiogram of the patient. The audiogram indicates bilateral profound sensorineural hearing loss, with pure-tone averages (PTAs) of 120 dB HL in the left ear and 113 dB HL in the right ear, and speech discrimination scores of 0% bilaterally.

otoacoustic emissions (DPOAEs) were entirely absent across all tested frequencies in both ears, yielding no clinically meaningful responses.

4)Clinical whole-exome sequencing (WES) of the patient's peripheral blood identified no definitive pathogenic variants within the NF2 locus or other related tumor-suppressor genes. Electroencephalography (EEG) recordings were markedly abnormal, demonstrating prominent interhemispheric asymmetry with slow-wave activity significantly more pronounced in the left prefrontal and anterior temporal leads, alongside paroxysmal epileptiform discharges characterized by sharp-wave clusters in the left anterior temporal leads. Motor conduction studies of the bilateral facial nerves demonstrated intact latencies and amplitudes, revealing no subclinical neuropathy. Furthermore, ophthalmological examination revealed profound bilateral visual deficits, with visual acuity restricted to counting fingers in both eyes; intraocular pressures were 13 mmHg in the left eye and 12 mmHg in the right eye. Fundoscopic examination revealed prominent bilateral optic disc pallor pathognomonic of advanced optic atrophy, while the mid-peripheral retina remained completely attached without evidence of hemorrhage. Optical coherence tomography (OCT) confirmed significant thinning of the bilateral retinal nerve fiber layer (RNFL).

3.2 Surgery and Postoperative Outcome Follow-up

In March 2024, the patient underwent right-ear cochlear implantation (CI) with a MED-EL Synchrony device and an FLEX28 electrode array at our hospital. Intraoperatively, electrically evoked auditory brainstem response (EABR) monitoring demonstrated well-differentiated, robust waveforms, confirming functional preservation of the cochlear nerve. Although a standard round window approach was initially planned for electrode insertion, advancement was physically obstructed at the basal turn of the cochlea due to soft-tissue tumor impingement. To bypass this barrier, the obliterated basal turn was meticulously drilled along the natural scalar trajectory via a localized cochleostomy, achieving a smooth, full-length electrode array insertion. Subsequent intraoperative telemetry demonstrated normal, stable impedance profiles across all active electrode channels, and initial electrical stimulation mapping yielded acceptable thresholds.

The patient demonstrated excellent auditory responsiveness during initial device activation at one week and subsequent programming at one month postoperatively (Fig. 3). Transient vertigo occurred within the first two weeks following activation but resolved spontaneously; notably, no facial nerve stimulation or facial muscle twitching was observed. At the three-month postoperative interval, her Category of Auditory Performance (CAP) score rapidly escalated to level 5. At the one-year follow-up, her CAP score had stabilized at level 6 (understands conversation without lipreading), while her Speech Intelligibility Rating (SIR) score reached level 5 (connected speech is intelligible to all listeners). Aided hearing thresholds demonstrated a remarkable improvement across all tested frequencies in the implanted right ear at the one-year interval (Fig. 4). Long-term electrical stimulation mapping at one year post-operation confirmed that electrode impedances and compliance profiles remained highly stable and safe across all channels (Fig. 5). Furthermore, her open-set disyllabic word recognition score reached 22% at a comfortable presentation level of 60 dB HL (Fig. 4), verifying a substantial and definitive improvement in functional speech intelligibility. Subjectively, the patient reported a dramatic reduction in daily communication barriers and a markedly enhanced capacity for active social participation.

4 Discussion

Although the underlying pathogenesis of neurofibromatosis type 2 (NF2) remains incompletely elucidated, definitive curative therapies are currently lacking in clinical practice (Pérez-Grau et al., 2010). As the disease progresses, NF2 patients characteristically encounter severe long-term morbidity and an increased risk of disease-specific mortality. These outcomes are driven predominantly by the persistent mass effect exerted by multiple intracranial tumors and cumulative treatment sequelae, profoundly compromising the patients' quality of life (Pérez-Grau et al., 2010).

4.1 Clinical Features and Research Advances in NF2

From a molecular perspective, mutations involving the *NF2* tumor-suppressor gene on chromosome 22q12.2 lead to the functional inactivation of its encoded protein, merlin. This inactivation subsequently dysregulates multiple downstream signaling networks, driving aberrant peripheral nerve sheath proliferation (Ahronowitz et al., 2007; Evans, 2009; Zuo et al., 2018; Okano et al., 2022; Halabi et al., 2023). Given the pronounced phenotypic heterogeneity inherent to this disease, establishing a definitive diagnosis of NF2 requires a comprehensive integration of clinical manifestations, high-resolution neuroradiological findings, and detailed molecular genomic sequencing (Neuro-Oncology Committee of the Chinese Anti-Cancer Association, 2021). Intriguingly, our patient exhibited a highly aggressive clinical course characterized by early-onset left anacusis at age 35, multiple recurrent intracranial tumors necessitating consecutive resections over 17 years, and suboptimally controlled secondary epilepsy. Crucially, her peripheral blood genetic evaluation revealed no pathogenic variants alongside a non-contributory family history, a combination pathognomonic of a rare somatic *NF2* mosaicism presenting with an extraordinarily high cranial tumor burden. Traditional therapeutic strategies for such advanced NF2 manifestations predominantly prioritize surgical debulking (Wang et al., 2023) or stereotactic Gamma Knife radiosurgery (Gao et al., 2019) to alleviate critical neural compression. More recently, targeted anti-VEGF monoclonal antibody therapy with bevacizumab has emerged as a key pharmacological intervention capable of temporarily stabilizing vestibular schwannoma volume and delaying surgical intervention (Lu et al., 2019; Shi et al., 2021; Brown, 2023). However, when systemic therapies fail to deliver sustained progression-free survival benefits and alternative or repurposed pharmacological options remain ineffective for refractory central nervous system lesions (Sanchez et al., 2021; Ghalavand et al., 2023; Tamura, 2023; Zhao et al., 2023), identifying the optimal window for functional cochlear implantation following extensive bevacizumab administration poses a formidable clinical challenge.

4.2 Vestibular Schwannoma Resection and Hearing Rehabilitation in NF2 Patients

The individualized selection of surgical approaches for managing neurofibromatosis type 2 (NF2)–related vestibular schwannomas is contingent upon tumor topology, mass volume, and preoperative cranial nerve functionality (Goldbrunner et al., 2020). Regarding functional auditory rehabilitation, clinical decision-making is heavily dictated by the anatomical integrity of the cochlea and the

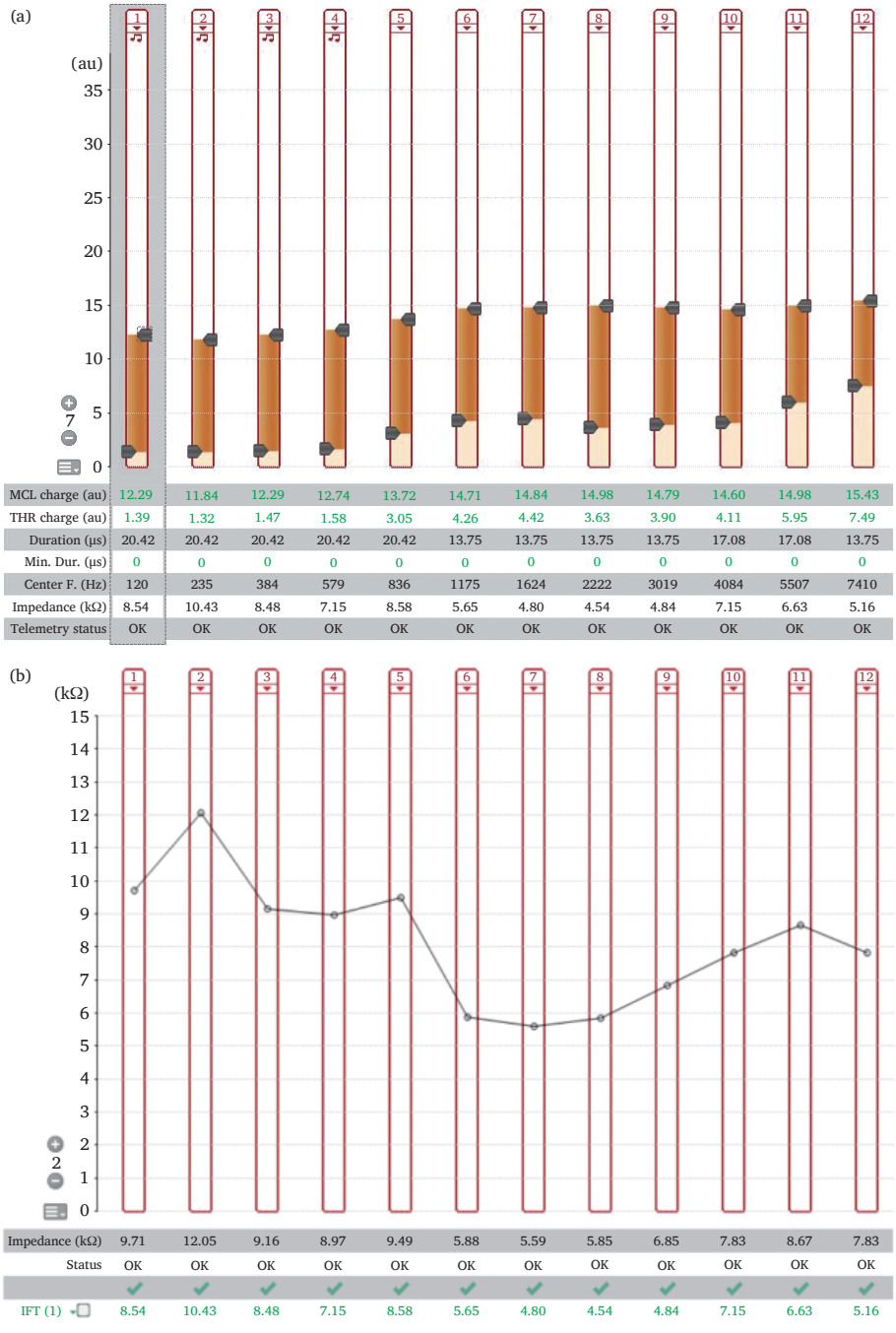

Figure 3 Postoperative electrical stimulation mapping results at one month. (a) Mapping profiles demonstrate acceptable stimulation levels across all active electrodes. (b) Telemetry curves show normal electrode impedance values across all active channels.

auditory nerve. When the cochlear nerve is inevitably sacrificed during oncological tumor extirpation, auditory brainstem implantation (ABI) remains the exclusive option, although its long-term open-set speech recognition outcomes are notoriously variable and unpredictable (Jiang and Zhang, 2015). Conversely, in patients whose cochlear architecture and retrocochlear neural pathways are anatomically preserved, cochlear implantation (CI) reliably yields vastly superior and more rapid auditory–verbal rehabilitation outcomes (Peng et al., 2018; Tadokoro et al., 2021).

However, managing patients with concurrent intracochlear or intralabyrinthine schwannomas presents profound surgical controversies. Historically, aggressive macro-resection of the tumor was deemed necessary to minimize recurrence risks, but this approach inevitably obliterates cochlear patency. More recently, an emerging paradigm shifts toward tumor-preserving in situ cochlear implantation, with international cohorts demonstrating promising long-term stability and speech perception gains without accelerating tumor kinetics (Huo et al., 2016; Eitutis et al., 2021; Laborai et al., 2022).

As the first reported case of tumor-preserving in situ cochlear implantation in an NF2 patient in China, this study represents a critical milestone addressing an intricate convergence of a high-burden oncological history and severe dual sensory impairment. Our patient endured a 17-year multi-tumor trajectory involving

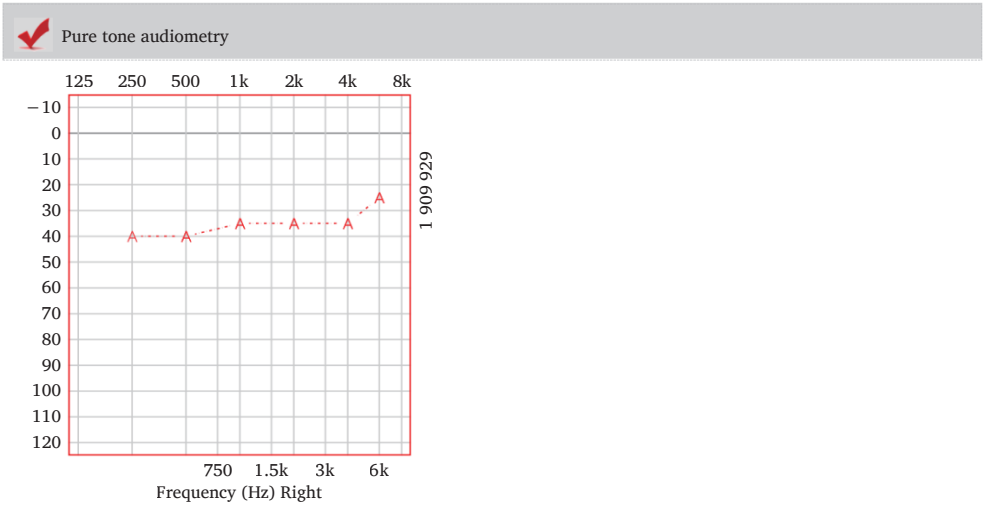

Speech recognition testing

	Average hearing threshold (dB HL)	Stimulus intensity (masking intensity) (dB HL)	Maximum speech recognition score (%)	Maximum speech recognition threshold (dB HL)
Right ear	35	60	22%	

Test material: Developed by the clinical hearing medicine center, department of otolaryngology-head and neck surgery

Figure 4 Postoperative audiological assessment at one year. The audiogram demonstrates a marked improvement in aided hearing thresholds within the implanted right ear across the entire tested frequency range (250–8,000 Hz). Additionally, the open-set disyllabic word recognition score reached 22% at a conversational presentation level of 60 dB HL.

multiple cranial and spinal resections, complicated by secondary refractory epilepsy. Most notably, her clinical profile was defined by pre-existing severe visual deprivation, with visual acuity limited to counting fingers bilaterally due to advanced optic atrophy. For conventional deaf individuals, visual cues such as lipreading provide essential communicative compensation. In this vulnerable deaf-blind cohort, the complete absence of auditory input results in catastrophic environmental alienation. Re-establishing a functional auditory pathway was therefore a paramount standalone necessity to restore her fundamental human connection and spatial orientation.

From a technical perspective, the primary intraoperative impediment was the complete mechanical obstruction at the basal turn of the cochlea caused by soft-tissue tumor impingement. Rather than forcing electrode advancement —which risks structural displacement or severe hemorrhage—we performed a precise micro-cochleostomy. By meticulously drilling open the obliterated basal segment along the natural scalar trajectory, we achieved a smooth, full-length insertion of the flexible MED-EL Synchrony electrode array. This technical success confirms that a soft, flexible electrode matrix, paired with cautious localized microdrilling, can safely bypass intralabyrinthine masses without disrupting inner ear microvascular or oncological stability.

Another pivotal clinical challenge involved balancing her preoperative targeted therapy with the surgical timeline. The patient completed seven cycles of bevacizumab prior to presentation. While anti-VEGF therapy can reduce microvascular tumor compression on adjacent neural substrates, its persistent anti-angiogenic effects present severe systemic risks, notably impaired wound healing, altered vascular compliance, and heightened liabilities for delayed bleeding. In our management protocol, the surgical intervention was precisely scheduled within a calculated therapeutic window. This allowed sufficient systemic clearance of the monoclonal antibody to minimize hemorrhagic and incisional complications, while effectively capturing the window before significant tumor rebound or hearing deterioration could recur.

The one-year follow-up metrics proved remarkably positive, validating the durability of this intervention. Telemetric mapping confirmed that electrochemical impedances and stimulation profiles across all active channels remained highly stable and safe (Fig. 5). Her aided hearing thresholds demonstrated a definitive improvement across the entire tested spectrum (Fig. 4). More critically, her open-set disyllabic word recognition score reached 22% at a conversational presentation level of 60 dB HL. Her Category of Auditory Performance (CAP) score escalated from a baseline of 0 to 6, indicating an ability to understand conversation entirely without lipreading, while her Speech Intelligibility Rating (SIR) score reached level 5. For a patient with concurrent near-total blindness, this functional hearing restoration bypasses her visual deficit, serving as a primary sensory anchor that significantly elevates her daily communicative autonomy and social safety.

In conclusion, within the highly volatile framework of somatic NF2 mosaicism presenting with an exceptionally heavy tumor burden, executing a tumor-preserving in situ cochlear implantation has proven both safe and highly efficacious. This definitive clinical success demonstrates that despite intricate anatomical distortions and complex prior targeted therapies, a meticulously timed and conservative ear-surgery strategy can successfully achieve long-term functional auditory rehabilitation, offering a vital technical precedent for managing similar complex syndromic populations worldwide.

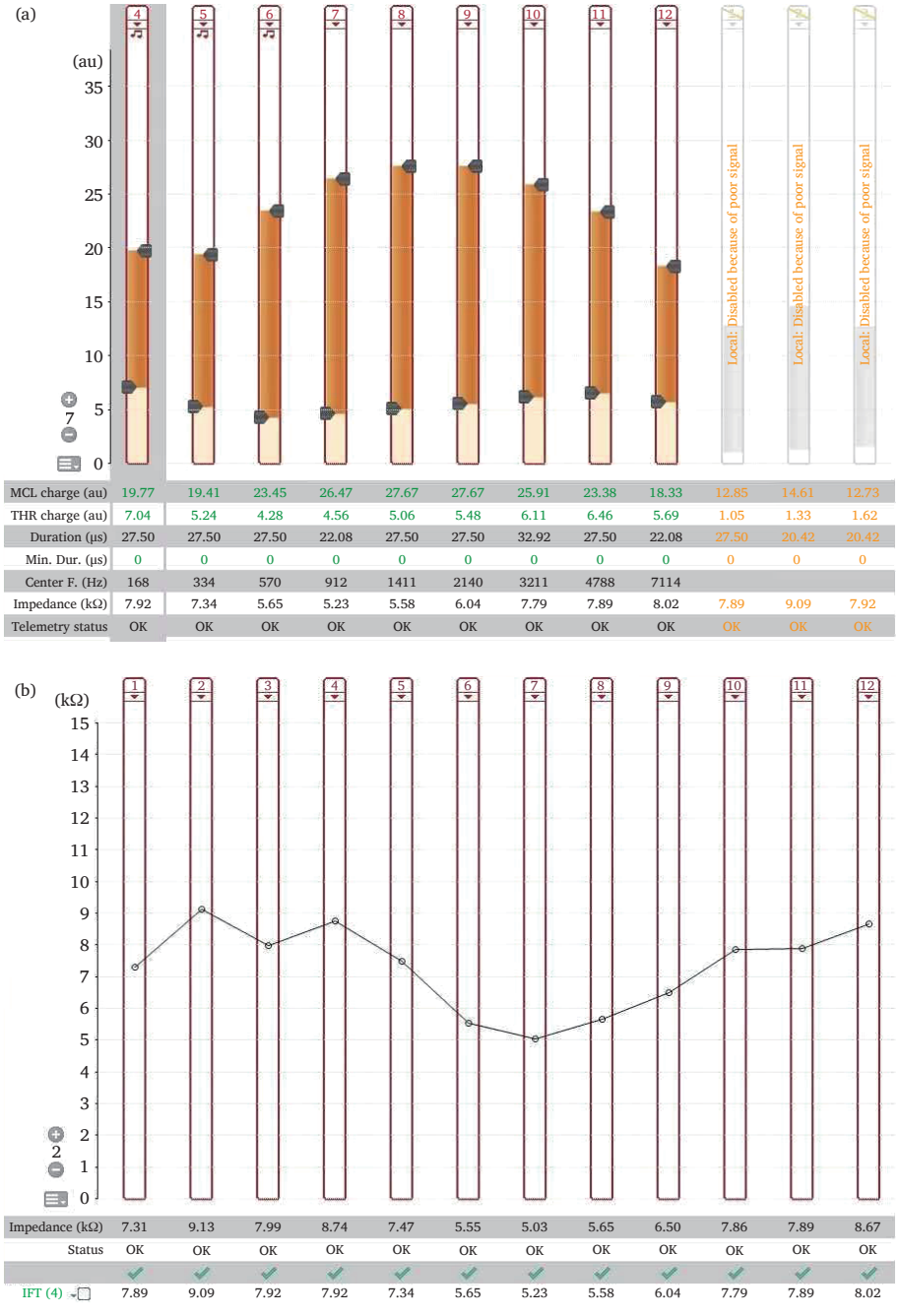

Figure 5 Long-term electrical stimulation mapping results at one year postoperatively. (a) Mapping profiles confirm acceptable stimulation levels across all active electrodes. (b) Telemetry curves demonstrate stable electrode impedance values across all active channels.

Funding

This work was supported by National Key R&D Program of China [grant number 2021YFF0702302].

Data availability statement

The datasets used during the current study are available from the corresponding author on reasonable request.

Ethical approval

This study, which included retrospective data analysis and prospective intraoperative testing, received formal ethical approval from the Medical Ethics Committee of Chinese PLA General Hospital (Approval Number: S2025-245-01). The study protocol adhered to the ethical principles outlined in the Declaration of Helsinki.

Informed consent

Written informed consent was obtained from the patient for the publication of this case report and the use of her clinical data for research purposes.

Conflicts of interest

The authors have no competing interests to declare that are relevant to the content of this article. The funders had no role in the

design of the study; in the collection, analyses, or interpretation of data; in the writing of the manuscript; or in the decision to publish the results

Acknowledgements

None.

Author contributions statement

Zhuang Boxiang: Conceptualization, Methodology, Formal analysis, Investigation, Writing – Original Draft.

Li Jianan: Conceptualization, Methodology, Formal analysis, Supervision, Writing – Review & Editing, Project administration, Funding acquisition.

Fu Linling: Writing – Original Draft, Writing – Review & Editing.

Wang Dandan: Writing – Original Draft, Writing – Review & Editing.

Hong Mengdi: Writing – Original Draft, Writing – Review & Editing.

All authors have read and approved the final manuscript and agree to be accountable for all aspects of the work.

References

Ahronowitz, I., Xin, W., Kiely, R., et al., 2007. Mutational spectrum of the NF2 gene: A meta-analysis of 12 years of research and diagnostic laboratory findings. *Hum. Mutat.* 28(1), 1–12.

Brown, R., 2023. Management of central and peripheral nervous system tumors in patients with neurofibromatosis. *Curr. Oncol. Rep.* 25(12), 1409–1417.

Neuro-Oncology Committee of the Chinese Anti-Cancer Association, 2021. Chinese expert consensus on multidisciplinary collaborative diagnosis and treatment strategy for nervous system tumors in neurofibromatosis type 2. Chin. J. Neurosurg. 37(7), 663–668.

Eitutis, S.T., Jansen, T., Borsetto, D., et al., 2021. Cochlear implantation in NF2 patients without intracochlear schwannoma removal. *Otol. Neurotol.* 42(7), 1014–1021.

Evans, D.G.R., 2009. Neurofibromatosis type 2 (NF2): A clinical and molecular review. *Orphanet J. Rare Dis.* 4(1), 16.

Gao, F.L., Li, M., Wang, Z., et al., 2019. Efficacy and safety of gamma knife radiosurgery for meningiomas in patients with neurofibromatosis type 2: A long-term follow-up single-center study. *World Neurosurg.* 125, e929–e936.

Ghalavand, M.A., Asghari, A., Farhadi, M., et al., 2023. The genetic landscape and possible therapeutics of neurofibromatosis type 2. *Cancer Cell Int.* 23(1), 99.

Goldbrunner, R., Weller, M., Regis, J., et al., 2020. EANO guideline on the diagnosis and treatment of vestibular schwannoma. *Neuro Oncol.* 22(1), 31–45.

Halabi, R., Dakroub, F., Haider, M.Z., et al., 2023. Unveiling a biomarker signature of meningioma: The need for a panel of genomic, epigenetic, proteomic, and RNA biomarkers to advance diagnosis and prognosis. *Cancers (Basel)* 15(22), 5339.

Huo, Z.R., Zhang, Z.H., Huang, Q., et al., 2016. Analysis of the effect of cochlear implant for the patients with acoustic neuroma in the only hearing ear. *Chin. J. Otorhinolaryngol. Head Neck Surg.* 51(6), 408–413.

Jiang, W., Zhang, H., 2015. Effects and new progress of auditory brainstem implantation. J. Audiol. Speech Pathol. 23(4), 435–437.

Laborai, A., Ghiselli, S., Cuda, D., 2022. Cochlear implant in patients with intralabyrinthine schwannoma without tumor removal. *Audiol. Res.* 12(1), 33–41.

Lu, V.M., Ravindran, K., Graffeo, C.S., et al., 2019. Efficacy and safety of bevacizumab for vestibular schwannoma in neurofibromatosis type 2: A systematic review and meta-analysis of treatment outcomes. *J. Neurooncol.* 144(2), 239–248.

Mankekar, G., Holmes, S., 2023. Hearing rehabilitation in vestibular schwannoma. *Audiol. Res.* 13(3), 357–366.

Okano, A., Miyawaki, S., Teranishi, Y., et al., 2022. Advances in molecular biological and translational studies in World Health Organization grades 2 and 3 meningiomas: A literature review. *Neurol. Med. Chir. (Tokyo)* 62(8), 347–360.

Peng, K.A., Lorenz, M.B., Otto, S.R., et al., 2018. Cochlear implantation and auditory brainstem implantation in neurofibromatosis type 2. *Laryngoscope* 128(9), 2163–2169.

Pérez-Grau, M., Miró, N., Prades, J., et al., 2010. Neurofibromatosis tipo 2: Neurofibromatosis type 2. *Acta Otorrinolaringol. Esp.* 61(4), 306–311.

Sanchez, L.D., Bui, A., Klesse, L.J., 2021. Targeted therapies for the neurofibromatoses. *Cancers (Basel)* 13(23), 6032.

Shi, J.W., Lu, D.F., Gu, R.X., et al., 2021. Reliability and toxicity of bevacizumab for neurofibromatosis type 2-related vestibular schwannomas: A systematic review and meta-analysis. *Am. J. Otolaryngol.* 42(6), 103148.

Tadokoro, K., Bartindale, M.R., El-Kouri, N., et al., 2021. Cochlear implantation in vestibular schwannoma: A systematic literature review. *J. Neurol. Surg. B Skull Base* 82(6), 643–651.

Tamura, R., 2021. Current understanding of neurofibromatosis type 1, 2, and schwannomatosis. *Int. J. Mol. Sci.* 22(11), 5850.

Tamura, R., 2023. Drug repositioning for refractory benign tumors of the central nervous system. *Int. J. Mol. Sci.* 24(16), 12997.

Wang, X.C., Li, S.W., Li, P., et al., 2023. Surgical strategy and outcome analysis of neurofibromatosis type 2. *Chin. J. Neurosurg.* 39(6), 546–550.

Zhao, R.G., Zou, W., Zhao, X.F., 2023. Treatment of neurofibromatosis type II with anlotinib: A case report and literature review. *Anticancer Drugs* 34(10), 1065–1068.

Zuo, W.J., Zong, L., Yang, S.M., 2018. Current research on pathogenesis of neurofibromatosis type 2. *Chin. J. Otol.* 16(4), 488–492.